

Hypoxia-associated factor expression in low-grade and anaplastic gliomas: a marker of poor outcome

Aurélie Tchoghandjian^{1,2}, Mei Y. Koh³, David Taieb^{1,2,4}, Sara Ganaha⁶, Garth Powis³, Emilie Bialecki⁵, Noël Graziani⁵, Dominique Figarella-Branger^{1,2,6}, Philippe Metellus^{2,5}

¹Aix-Marseille Université, Faculté de Médecine, Marseille, 13385 Cedex 05, France

²INSERM, UMR 911, CRO2, Faculté de Médecine, Marseille, 13385 Cedex 05, France

³Sanford-Burham Medical Research Institute, Basic Laboratory Cancer Center, La Jolla, 92037 California, USA

⁴Department of Nuclear Medicine, Assistance Publique-Hôpitaux de Marseille, Hôpital de la Timone, Marseille, 13385 Cedex 05, France

⁵Department of Neurosurgery, Centre Hospitalier Clairval, Ramsay Generale de Sante, Marseille, 13009, France

⁶Department of Neuropathology, Assistance Publique-Hôpitaux de Marseille, Hôpital de la Timone, Marseille, 13385 Cedex 05, France

Correspondence to: Philippe Metellus, **e-mail:** Philippe.metellus@outlook.fr

Keywords: low-grade gliomas, anaplastic gliomas, isocitrate dehydrogenase (IDH), hypoxia-inducible factor (HIF), hypoxia-associated factor (HAF)

Received: September 10, 2015

Accepted: February 20, 2016

Published: March 14, 2016

ABSTRACT

Somatic mutations in isocitrate dehydrogenase (IDH) genes have recently been identified in a large proportion of glial tumors of the CNS and reported to be a strong prognostic factor in gliomas whatever the tumor grade. Few data are available in the literature regarding the relationship between IDH mutations and HIF expression in low-grade gliomas (LGGs), especially in a recently described aggressive molecular subtype: “triple negative” (IDH non mutated, 1p 19q non codeleted, p53 expression negative) gliomas. We analyzed clinical, radiological and molecular features of a series of 31 grade II/III gliomas. p53 expression, 1p19q deletion and IDH mutation status were provided for all tumors. Also HIF (hypoxia inducible factor)-1 α , HIF-2 α , HAF, Sox2 (SRY(Sex determining region Y)-box2) and OCT (octamer binding factor) 3/4 expressions were analyzed. We found positive HIF-2 α staining in 38.7% of cases which was uncorrelated to HIF-1 α expression or *IDH1/2* mutation status. However, HIF-2 α staining was significantly associated with HAF expression, a stem-like cell marker, in the whole population. HAF expression was present in 74.2% of cases and significantly correlated to Sox2 expression. Furthermore, HAF expression was significantly associated with the “triple negative” glioma phenotype. We provide here first evidence that HAF, a stem-like cell marker, expression is highly correlated to the triple negative aggressive LGG/AG molecular phenotype suggesting that these tumours might arise from cells of different origin.

INTRODUCTION

Somatic mutations in isocitrate dehydrogenase enzyme isoforms 1 (*IDH1*) and 2 (*IDH2*) genes (*IDH1/2*) have recently been identified in a large proportion of glial tumors of the CNS (Central nervous System) [1-4]. *IDH1* mutation has been reported to be a strong and independent indicator for good prognosis in gliomas whatever the tumor grade [5-10].

The biochemical consequences of *IDH1* mutations are complex and remain controversial. It was initially reported that *IDH1* mutations led to HIF-1 stabilization, a finding which was attributed to an inhibition of PHDs (propyl hydroxylases) by 2-HG (2-hydroxy-glutarate), a widely accepted mechanism for the succinate and fumarate in *SDH* (succinate dehydrogenase) or *FH* (*fumarate hydroxylase*)-related tumors, respectively. However,

there are conflicting results regarding the role of HIF-1 in *IDH1/2*-related tumors. Koivunen *et al* reported that 2-HG efficiently inhibits a number of 2-OG-dependent dioxygenases, but does not inhibit PHDs. Instead, 2-HG was capable of promoting the activity of PHD1 and 2, and to a lesser extent, the activity of PHD3, leading to the downregulation of the amount of HIF-1 α [11]. Taken together, the findings challenge the current HIF-hypothesis in *IDH1/2*-mutated tumors.

We recently showed that *IDH1/2*-related low-grade and anaplastic gliomas were not associated with an activation of HIF-1 α [12] and HIF-1 α overexpression was restricted to necrotic areas. These results are consistent with the findings of Williams *et al* [13]. However, it has recently become clear that HIF-1 α , and its closely-related isoform, HIF-2 α , act in concert in regulating the response to hypoxia, exhibiting unique functions such as the regulation of the glycolytic enzymes and PDK1 by HIF-1 α , and erythropoiesis and cellular iron metabolism by HIF-2 α , while also sharing some redundancies such as in the regulation of angiogenesis, lipid metabolism, and metastasis [14]. A recent study showed that chronic hypoxic or pseudo-hypoxic conditions were associated with a switch from HIF1-alpha to HIF-2 α [15], a finding which seems to occur naturally as well as during tumorigenesis. The hypoxia-associated factor (HAF) is an isoform specific E3 ubiquitin ligase that specifically degrades HIF-1 α but not HIF-2 α , and promotes HIF-2 α transactivation, thus promoting the switch from HIF-1 to HIF-2 dependent transcription [16-18]. The consequences of the shift towards HIF-2 dependent transcription include a shift towards an undifferentiated phenotype, which is typically associated with more aggressive disease. Until the present, no data exists regarding the expression of HIF-2 α in gliomas.

Therefore, we have evaluated the expression of HAF, HIF-2 α and HIF-1 α targets genes (Sox2, OCT3/4) in a cohort of low grade gliomas (LGGs) and anaplastic gliomas (AGs).

RESULTS

According to the WHO classification, there were 23 (74.2%) grade II and 8 (25.8%) grade III gliomas. All tumors were supratentorial. Histologically there were 4 (12.9%) astrocytomas, 12 (38.7%) oligoastrocytomas and 15 (48.4%) pure oligodendrogliomas. Necrosis was absent in all cases. WHO grade or histological type were not significantly associated with *IDH* status. 1p19q deletion was found in 10/18 (55.5%, $p=0.001$) of *IDH* mutated tumors and p53 expression in 9/18 (50%; $p=0.003$) of these *IDH* mutated tumors.

All 31 tumors were analyzed for the presence of codons 132 and 172 mutations on the *IDH1* and *IDH2* genes respectively. *IDH* mutations were found in 18/31 (60.6%) tumors. Sequence analysis of exon

4 of *IDH1* gene revealed mutations in 17 out of 31 (54.8%) patients at residue R132, including 15/17 (88.2) R132H (p.Arg132His, c.395G>A), 1/17 (5.6%) R132C (p.Arg132Cys, c.394C>T) and 1/17 (5.6%) R132S (p.Arg132Ser, c.394C>A). Sequence analysis of exon 4 of the *IDH2* gene revealed 1/31 mutation (5.8%) at residue R172M (p.Arg172Met, c.515G>T). This patient harbored pure oligodendroglioma as reported by others [19].

Sex ratio was 1.38 (18 male and 13 female), and median age was 40 years (range, 22-71 years). Triple negative (*IDH* non mutated, 1p 19q non codeleted, p53 expression negative) tumor patients presented with a significantly higher age (55.5yrs vs 37.5yrs, $p=0.002$). The characteristics of this population are listed in Table 1.

HAF, HIF-2 α , HIF-1 α , Sox2 and OCT3/4 expression

We found that HAF expression was present in 74.2% of cases and was significantly correlated to Sox2 expression, a stem-cell marker ($p=0.02$). Furthermore, HAF expression was significantly associated ($p=0.0004$) with the “triple negative” glioma phenotype, we previously described, that combines *IDH*-non mutated, p53 non mutated and 1p19q non deleted tumors (Figure 1, Table 1) [7, 8]. Triple negative gliomas share peculiar clinical characteristics, radiologic presentation, molecular features and dismal prognosis. Indeed, their median overall survival is significantly worse than their *IDH* mutated counterparts as reported by others [9, 10, 20]. Here, we first provide evidence that HAF expression is highly correlated to this aggressive glioma molecular phenotype.

Interestingly, we found positive HIF-2 α staining in 38.7% of cases which was uncorrelated to HIF-1 α expression or *IDH1/2* mutation status. However, HIF-2 α staining was significantly associated with HAF expression in the whole population ($p=0.002$). There was also a trend toward correlation between positive HIF-2 α expression and HAF expression in *IDH* mutated tumors ($p=0.08$).

Finally OCT3/4 immunostaining was negative in all tumors.

Triple negative tumors were associated with a peculiar clinical features, radiologic presentation and dismal prognosis

A total of 13 patients harbored neither *IDH1* nor *IDH2* mutations. These tumors occurred in older patients (>40 year-old, $P=0.002$). All these 13 tumors (100%) displayed a marked (score=2) infiltrative pattern on MR imaging whereas only 8/18 (44.5%) of mutated ones had this infiltration score ($P = 0.0004$). Axial T2 largest diameter was significantly greater (10/13 vs 6/12) in non-mutated tumors ($P = 0.02$). Greater extent of surgery (GTR and STR) was significantly lower in this group (2/13 vs 12/18, $P<0.003$).

Table 1: Patients and tumor characteristics

Variables	All patients Number of pts (%) (n=31)	IDH mutated gliomas Number of pts (%) (n=18)	Triple negative gliomas Number of pts (%) (n=13)	P-value
Age				0.002
Median	40 yrs	37.5 yrs	55.5 yrs	
Mean (+/-SD)	45.2 +/-14.2 yrs	37.8+/- 12.2 yrs	54.4 +/- 12.4 yrs	
Range	22-71 yrs	22-63 yrs	27-71 yrs	
Sex				0.971
Male	18 (60.6%)	10 (55.5%)	8 (61.5%)	
Female	13 (39.4%)	8 (44.5%)	5 (38.5%)	
Histology grade				0.07
WHO II	23 (74.2%)	16 (88.9%)	7 (53.8%)	
WHO III	8 (25.8%)	2 (11.1%)	6 (46.2%)	
Histology type				0.189
Astrocytoma	4 (12.9%)	2 (11.1%)	2 (15.4%)	
Oligoastrocytoma	12 (38.7%)	5 (27.8%)	7 (53.8%)	
Oligodendroglioma	15 (48.4%)	11 (61.1%)	4 (30.8%)	
p53 expression				0.003
Yes	9 (29.0 %)	9 (50.0%)	0 (0%)	
No	22 (71.0 %)	9 (50.0%)	13 (100%)	
1p19q deletion				0.001
Yes	10 (32.3%)	10 (55.5%)	0 (0%)	
No	21 (67.7%)	8 (44.5%)	13 (100%)	
IHC HIF1 α				0.847
Yes	4 (12.9%)	3 (16.6%)	1 (7.7%)	
No	27 (87.1%)	15 (83.4.0%)	12 (92.3%)	
IHC HIF2 α				0.469
Yes	12 (38.7%)	6 (33.3%)	6 (46.2%)	
No	19 (61.3 %)	12 (67.7%)	7 (53.8%)	
IHC HAF				0.002
Yes	23 (74.2%)	10 (55.5%)	13 (100%)	
No	8 (25.8%)	8 (44.5%)	0 (0%)	
IHC Sox2				0.09
Yes	16 (51.6%)	7 (38.9%)	9 (69.2%)	
No	15 (48.4%)	11 (61.1%)	4 (30.8%)	

SD=standard deviation

Also temporo-insular location was significantly higher in this group (1/13 vs 13/18, $P=0.0007$). Necrosis was absent in all cases (Table 2). A typical case of this clinical, radiologic and

molecular subgroup is shown in Figure 1 (first column) along with a well-delineated fronto-temporo-insular *IDH*-mutated tumor Figure 1 (second column).

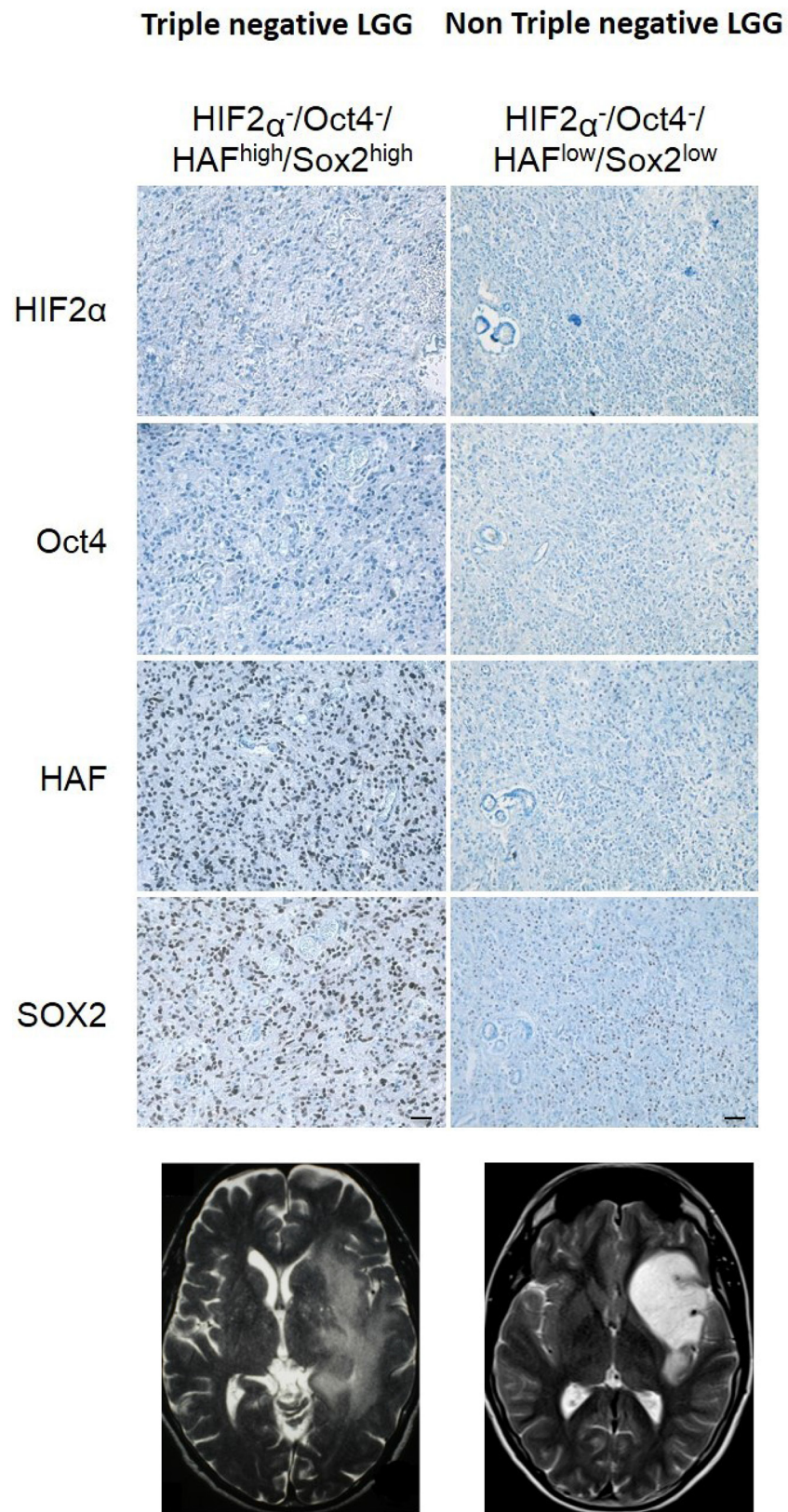


Figure 1: First column: Immunohistochemistry analysis of a triple negative LGG showing absence of OCT3/4 and HIF-2 α immunostaining, and high level of HAF and Sox2 immunostaining. Axial T2-weighted sequences MRI-scan displayed a huge infiltrative glioma with a temporo-insular topography. **Second column:** Immunohistochemistry analysis of a non-triple negative LGG showing absence of OCT3/4 and HIF-2 α immunostaining, and low level of HAF and Sox2 immunostaining. Axial T2-weighted sequences MRI-scan displayed a sharp border glioma with a fronto-insular topography.

Table 2: Tumor radiologic features and extent of surgery

Variables	All patients Number of pts (%) (n=31)	IDH mutated gliomas Number of pts (%) (n=18)	Triple negative gliomas Number of pts (%) (n=13)	P-value
Max diameter on T2 axial MRI-scan				0.02
> 6 cm	16 (51.6%)	6 (33.3%)	10 (76.9%)	
≤ 6 cm	15 (48.4%)	12 (66.7%)	3 (23.1%)	
MRI Infiltrative score				0.0004
1	10 (32.3%)	10 (55.5%)	0 (0%)	
2	21 (67.7%)	8 (44.5%)	13 (100%)	
Topography				0.0007
Temporo-insular	17 (54.8%)	5 (27.8%)	12 (92.3%)	
Non temporo-insular	14 (45.2%)	13 (72.2%)	1 (7.7%)	
Extent of surgery				0.003
Biopsy/PR	17 (54.8%)	6 (33.3%)	11 (84.6%)	
STR/GTR	14 (45.2%)	12 (66.7%)	2 (15.4%)	

Molecular profile predicts outcome of LGGs and AGs

We analyzed the prognostic impact of *IDH1* and *IDH2* mutations in our population. Triple negative patients had a median OS time of 36 months and a 5-year survival rate of 36%. Median OS time was not reached for patients with either *IDH1* or *IDH2* mutations and 5-year survival rate was 90.1% ($P < 0.001$) (Figure 2). Patients with overexpression of HAF had a median OS time of 56 months and a 5-year survival rate of 47%. Median OS time was not reached for patients with no overexpression of HAF and 5-year survival rate was 80.2% ($P < 0.001$) (Figure 3).

DISCUSSION

HAF expression has already been described as a stem-like cell marker in glioblastomas, involved in neoangiogenesis [21, 22]. Although LGGs share the same histological phenotype, the differences in biology and clinical prognosis of LGGs suggest that these tumors might arise from cells of different origin.

Multipotent neural stem cells (NSC) and progenitors derived from developing or adult central nervous system (CNS) can be isolated and propagated in culture in the presence of mitogens. This involves the generation of free-floating spherical clusters, termed “neurospheres” [23]. Neurospheres consist of both multipotent stem cells and more restricted progenitors at different stages of differentiation. In addition to the heterogeneity that occurs

within neurospheres, there is evidence that neurospheres derived from different regions of the developing or adult brain display unique characteristics with regards to growth, differentiation and gene expression [24]. Previous studies have shown that primary human brain tumors especially glioblastoma (GBM) contain cells with NSC features suggesting that GBMs may occur after malignant transformation of NSCs or progenitors [25-29]. In contrast to *IDH* mutated LGGs, the “triple negative” subgroup presents a rapid malignant course with worse clinical outcome [8]. Thus it is likely that several types of brain tumor-initiating cells play a role in LGGs initiation. Furthermore, the peculiar radiological aspect and preferred temporo-insular location of these tumors are consistent with such a developmental hypothesis. The clinical behavior, response to therapy of these aggressive gliomas is challenging. Recently, several molecular studies on gliomas highlighted a potential complex ordered processes of multiple clonal selection and evolutionary event that support this developmental hypothesis [30-33].

The human insular cortex, is considered the developmentally most primitive lobe of the telencephalon [34]. Three architectonical areas have been described within the insular cortex, an anterior agranular area, a mid-dysgranular area and a posterior granular area [35]. Also a chemoarchitectonical organization of the insula parallels the structural cytoarchitectonical one [36]. Thus the embryological development of the human insula has led to a heterogenous cytochemoarchitectonic and functional interface between a multimodal area (prefrontal cortex) and a primary area (sensorimotor and auditory cortex)

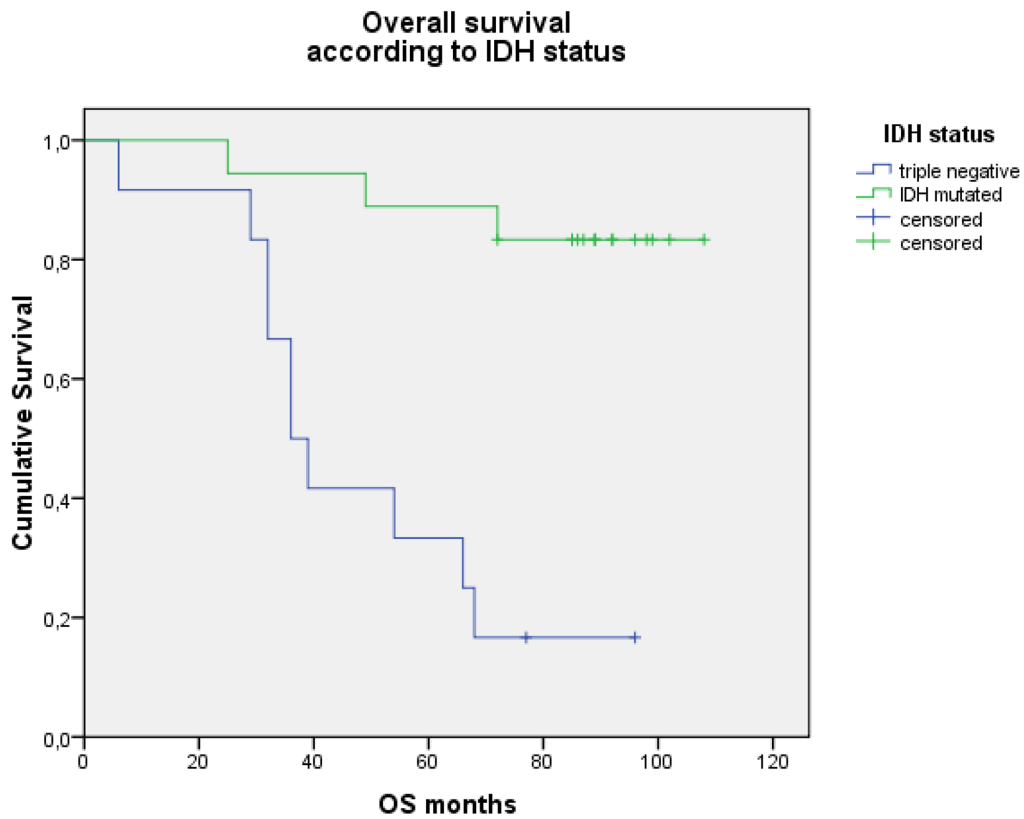


Figure 2: Comparison of Kaplan-Meier overall survival curves according to IDH status (log-rank test, $P < 0.001$).

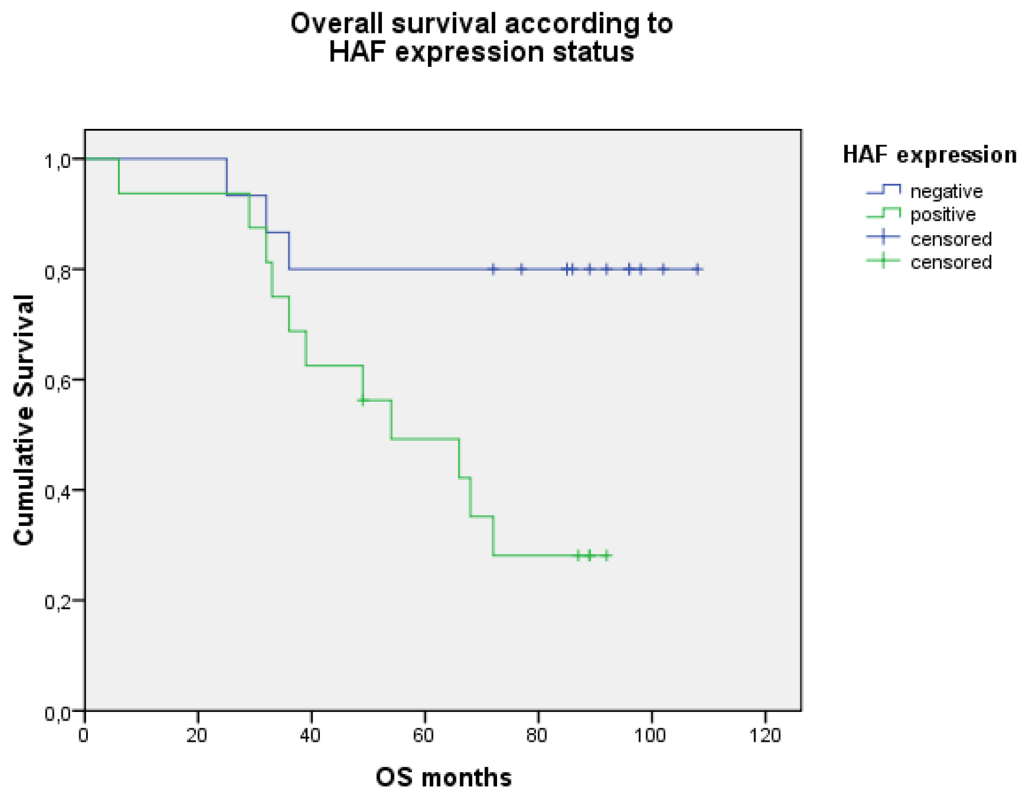


Figure 3: Comparison of Kaplan-Meier overall survival curves according to HAF expression level (log-rank test, $P < 0.001$).

[37]. It can be hypothesized that this developmental heterogeneity could be subserved by a stem- or progenitor cells heterogeneous distribution locally and that gliomagenesis could result from a peculiar cross-talk between micro-environment and specific glial cells. Molecular heterogeneity of low-grade gliomas involving the insula would probably reflect this local structural and functional heterogeneity.

This study has actual limits since it is a retrospective analysis of a small cohort and we do not know that no definitive conclusions could be drawn by this work. However, it raises some interesting and relevant questions regarding gliomagenesis.

Here, we provide first evidence that HAF expression, a stem-like cell marker, is significantly associated with a peculiar glioma molecular profile responsible for a worse outcome and is also correlated to Sox2 expression. Interestingly, Sox2, a transcription factor that serves key functions during embryogenic development and is involved in cancer stem cell maintenance has been recently identified as useful independent prognostic factors in gliomas [38, 39]. Also, we demonstrated that HIF-2 α expression was significantly associated with HAF expression in the whole population but not so clearly in the triple negative subgroup. Thus, whether undifferentiated and aggressive phenotype of triple negative gliomas is HIF-2 α dependent or independent could not be asserted and needs to be investigated further. However, our data suggest that HAF expression could identify a specific subgroup of LGG with malignant transformation potential that should be taken into account to better tailor monitoring and treatment strategies.

MATERIALS AND METHODS

Human tumor samples data

La Timone University Hospital Center Pathology database was queried for all archival surgical specimens of World Health Organization (WHO) grade II and III gliomas between 2008 and 2012 and then crossed with the Imaging database for pretherapeutic MRI available data. A total of 31 of 332 newly diagnosed patients with grade II or grade III glioma were included in this retrospective study. All patients were operated at our institution (Assistance Publique-Hôpitaux de Marseille, Marseille, France). Tumor specimens were obtained according to a protocol approved by the local institutional review board, ethics committee and conducted according to national regulations. All the patients provided written informed consent. All analyzed brain tumors were subjected to review by a single neuropathologist (DFB). In this study, all patients were first time operated on without prior history of radiation or chemotherapy. For all patients, clinical, radiological data, and follow-up were collected as previously reported [8].

1p19q and p53 status analysis

All analyses were performed on 5 μ m tissue sections of formalin-fixed paraffin-embedded tissues when tissue material was available (Bouin-fixed tissues were not used). Presence of 1p19q deletion was studied in all samples by fluorescent *in situ* hybridization (FISH) with locus-specific probes for 1p36 and 19q13 as previously described [40]. In order to detect TP53 protein overexpression (DO-7 clone, 1/200, Dako, Trappes, France) in all samples, an automated immunohistochemistry (IHC) analysis was performed with avidin-biotin-peroxydase complex on the BenchMark XT system (Ventana Medical Systems, Tucson, Ariz) with a Ventana kit that included 3,3'-diaminobenzidine reagent.

Genomic DNA extraction

Areas of viable and representative tumor following review of all blocks were marked by a single neuropathologist (DFB). Then, for the 31 samples, tumor DNA was extracted from twenty 10 μ m sections of formalin-fixed paraffin-embedded tissues using the QIAmp DNA minikit, as described by the manufacturer (Qiagen, Courtaboeuf, France). Spectrophotometric quantification was performed on a Nanodrop ND-100 (Labtech, Palaiseau, France) and all DNA samples were diluted to 25 ng/ μ l.

IDH1 codon 132 and IDH2 codon 172 sequence analysis

IDH1 and *IDH2* alterations of the mutational hotspot codons R132 and R172 were assessed by PCR amplification and direct DNA sequencing. First, genomic regions spanning codons R132 and R172 were amplified by classic PCR on a MJ Research PCT-100 thermocycler. Briefly, PCR amplification was performed in a total volume of 20 μ l, consisting of 1 μ l of DNA solution (25 ng/ μ l), 1 μ l of forward and reverse primers (5 μ M), and 10 μ l of 2X PCR Master Mix (Abgene, Courtaboeuf, France). Then, direct DNA sequencing for *IDH1* and *IDH2* mutations was performed by Beckman Coulter Genomics sequencing service (Takeley, United Kingdom) from purified PCR products using the same specific primers as previously described [12].

IDH1, HIF-1 α , HIF-2 α , HAF, Sox2, OCT3/4 immunohistochemistry

R132H mutated form of IDH1, Hypoxia Inducible Factor (HIF-1 α and HIF-2 α) HAF, Sox2 and OCT3/4 immunohistochemistry analyses were carried out on all glioma samples. After steam-heat-induced antigen retrieval, 5 micrometer serial sections of formalin-fixed paraffin-embedded samples were tested for the presence of IDH1 R132H (mouse monoclonal antibody, H09 clone, Dianova, Germany), HIF-1 α (rabbit polyclonal

antibody, 1:50, gift from J. Pouyssegur, Nice, France), of HIF-2 α (ep190b, 1:100, mouse IgG1, Abcam, Paris, France), OCT3/4 (1:1000, goat IgG, Santa Cruz), HAF (GST-SART-1, purified mouse monoclonal antibody, 1:100, custom made at the Core Immunology, MD Anderson, Texas) and SOX2 (clone SP76, rabbit IgG, pre-diluted, Ventana Medical Systems SA, Illkirch, France). A Benchmark Ventana autostainer (Ventana Medical Systems SA) was used for detection, and slides were simultaneously immunostained to avoid inter-manipulation variability. Slides were then scanned (Nanozoomer 2.0-HT, Hamamatsu Photonics SARL France, Massy, France) and images processed in NDP.view2 software (Hamamatsu). Tumors were classified as positive when the percentage of immunostaining cells was superior to the median expression in the whole population.

Statistical analysis

To compare patients' characteristics according to IDH status, we used Pearson's chi-square test, Fisher's exact test and U Mann-Whitney test. *P*values of less than 0.05 were considered significant for each statistical analysis. Survivals were estimated by using the Kaplan-Meier method and curves were compared by using the log-rank test. (PASW Statistics 17.0).

ACKNOWLEDGMENTS

We are grateful to Dr David Zagzag for his thorough reviewing and input in the manuscript editing.

This work was supported by the INCa Grant SIRIC and APHM Tumor Bank Authorization Number 2008/70.

CONFLICTS OF INTEREST

The authors declare that they have no conflicts of interest related to this article.

REFERENCES

- Balss J, Meyer J, Mueller W, Korshunov A, Hartmann C and von Deimling A. Analysis of the IDH1 codon 132 mutation in brain tumors. *Acta Neuropathol.* 2008; 116:597-602.
- Bleeker FE, Lamba S, Leenstra S, Troost D, Hulsebos T, Vandertop WP, Frattini M, Molinari F, Knowles M, Cerrato A, Rodolfo M, Scarpa A, Felicioni L, Buttitta F, Malatesta S, Marchetti A, et al. IDH1 mutations at residue p.R132 (IDH1(R132)) occur frequently in high-grade gliomas but not in other solid tumors. *Hum Mutat.* 2009; 30:7-11.
- Parsons DW, Jones S, Zhang X, Lin JC, Leary RJ, Angenendt P, Mankoo P, Carter H, Siu IM, Gallia GL, Olivi A, McLendon R, Rasheed BA, Keir S, Nikolskaya T, Nikolsky Y, et al. An integrated genomic analysis of human glioblastoma multiforme. *Science.* 2008; 321:1807-1812.
- Yan H, Parsons DW, Jin G, McLendon R, Rasheed BA, Yuan W, Kos I, Batinic-Haberle I, Jones S, Riggins GJ, Friedman H, Friedman A, Reardon D, Herndon J, Kinzler KW, Velculescu VE, et al. IDH1 and IDH2 mutations in gliomas. *N Engl J Med.* 2009; 360:765-773.
- Sanson M, Marie Y, Paris S, Idbaih A, Laffaire J, Ducray F, El Hallani S, Boisselier B, Mokhtari K, Hoang-Xuan K and Delattre JY. Isocitrate dehydrogenase 1 codon 132 mutation is an important prognostic biomarker in gliomas. *J Clin Oncol.* 2009; 27:4150-4154.
- van den Bent MJ, Dubbink HJ, Marie Y, Brandes AA, Taphoorn MJ, Wesseling P, Frenay M, Tijssen CC, Lacombe D, Idbaih A, van Marion R, Kros JM, Dinjens WN, Gorlia T and Sanson M. IDH1 and IDH2 Mutations Are Prognostic but not Predictive for Outcome in Anaplastic Oligodendroglial Tumors: A Report of the European Organization for Research and Treatment of Cancer Brain Tumor Group. *Clin Cancer Res.* 2010.
- Figarella-Branger D, Bouvier C, de Paula AM, Mokhtari K, Colin C, Loundou A, Chinot O and Metellus P. Molecular genetics of adult grade II gliomas: towards a comprehensive tumor classification system. *Journal of neuro-oncology.* 2012; 110:205-213.
- Metellus P, Coulibaly B, Colin C, de Paula AM, Vasiljevic A, Taieb D, Barlier A, Boisselier B, Mokhtari K, Wang XW, Loundou A, Chapon F, Pineau S, Ouafik L, Chinot O and Figarella-Branger D. Absence of IDH mutation identifies a novel radiologic and molecular subtype of WHO grade II gliomas with dismal prognosis. *Acta Neuropathol.* 2010; 120:719-729.
- Sabha N, Knobbe CB, Maganti M, Al Omar S, Bernstein M, Cairns R, Cako B, von Deimling A, Capper D, Mak TW, Kiehl TR, Carvalho P, Garrett E, Perry A, Zadeh G, Guha A, et al. Analysis of IDH mutation, 1p/19q deletion, and PTEN loss delineates prognosis in clinical low-grade diffuse gliomas. *Neuro-oncology.* 2014; 16:914-923.
- Sun H, Yin L, Li S, Han S, Song G, Liu N and Yan C. Prognostic significance of IDH mutation in adult low-grade gliomas: a meta-analysis. *Journal of neuro-oncology.* 2013; 113:277-284.
- Koivunen P, Lee S, Duncan CG, Lopez G, Lu G, Ramkissoon S, Losman JA, Joensuu P, Bergmann U, Gross S, Travins J, Weiss S, Looper R, Ligon KL, Verhaak RG, Yan H, et al. Transformation by the (R)-enantiomer of 2-hydroxyglutarate linked to EGLN activation. *Nature.* 2012; 483:484-488.
- Metellus P, Colin C, Taieb D, Guedj E, Nanni-Metellus I, de Paula AM, Colavolpe C, Fuentes S, Dufour H, Barrie M, Chinot O, Ouafik L and Figarella-Branger D. IDH mutation status impact on in vivo hypoxia biomarkers expression: new insights from a clinical, nuclear imaging and immunohistochemical study in 33 glioma patients. *J Neurooncol.* 2011; 105:591-600.
- Williams SC, Karajannis MA, Chiriboga L, Golfinos JG, von Deimling A and Zagzag D. R132H-mutation of isocitrate

- dehydrogenase-1 is not sufficient for HIF-1 α upregulation in adult glioma. *Acta Neuropathol.* 2011; 121:279-281.
14. Keith B, Johnson RS and Simon MC. HIF1 α and HIF2 α : sibling rivalry in hypoxic tumour growth and progression. *Nature reviews Cancer.* 2012; 12:9-22.
 15. Koh MY and Powis G. Passing the baton: the HIF switch. *Trends in biochemical sciences.* 2012; 37:364-372.
 16. Koh MY, Lemos R, Jr., Liu X and Powis G. The Hypoxia-Associated Factor Switches Cells from HIF-1{ α }- to HIF-2{ α }-Dependent Signaling Promoting Stem Cell Characteristics, Aggressive Tumor Growth and Invasion. *Cancer Res.* 2011; 71:4015-4027.
 17. Koh MY, Darnay BG and Powis G. Hypoxia-Associated Factor, a Novel E3-Ubiquitin Ligase, Binds and Ubiquitinates Hypoxia-Inducible Factor 1 α , Leading to Its Oxygen-Independent Degradation. *Molecular and Cellular Biology.* 2008; 28:7081-7095.
 18. Gupta M, Mungai PT and Goldwasser E. A new transacting factor that modulates hypoxia-induced expression of the erythropoietin gene. *Blood.* 2000; 96:491-497.
 19. Hartmann C, Meyer J, Balss J, Capper D, Mueller W, Christians A, Felsberg J, Wolter M, Mawrin C, Wick W, Weller M, Herold-Mende C, Unterberg A, Jeuken JW, Wesseling P, Reifenberger G, et al. Type and frequency of IDH1 and IDH2 mutations are related to astrocytic and oligodendroglial differentiation and age: a study of 1,010 diffuse gliomas. *Acta Neuropathol.* 2009; 118:469-474.
 20. Kim YH, Lachuer J, Mittelbronn M, Paulus W, Brokinkel B, Keyvani K, Sure U, Wrede K, Nobusawa S, Nakazato Y, Tanaka Y, Vital A, Mariani L and Ohgaki H. Alterations in the RB1 pathway in low-grade diffuse gliomas lacking common genetic alterations. *Brain pathology (Zurich, Switzerland).* 2011; 21:645-651.
 21. Seidel S, Garvalov BK, Wirta V, von Stechow L, Schanzer A, Meletis K, Wolter M, Sommerlad D, Henze AT, Nister M, Reifenberger G, Lundeberg J, Frisen J and Acker T. A hypoxic niche regulates glioblastoma stem cells through hypoxia inducible factor 2 α . *Brain.* 2010; 133:983-995.
 22. Shin B, Burkhardt JK and Boockvar J. Glioblastoma multiforme stem-like cells and hypoxia: the novel role of HAF. *Neurosurgery.* 2011; 69:N21.
 23. Reynolds BA and Weiss S. Generation of neurons and astrocytes from isolated cells of the adult mammalian central nervous system. *Science.* 1992; 255:1707-1710.
 24. Ostenfeld T, Joly E, Tai YT, Peters A, Caldwell M, Jauniaux E and Svendsen CN. Regional specification of rodent and human neurospheres. *Brain research Developmental brain research.* 2002; 134:43-55.
 25. Galli R, Binda E, Orfanelli U, Cipelletti B, Gritti A, De Vitis S, Fiocco R, Foroni C, Dimeco F and Vescovi A. Isolation and characterization of tumorigenic, stem-like neural precursors from human glioblastoma. *Cancer Res.* 2004; 64:7011-7021.
 26. Hemmati HD, Nakano I, Lazareff JA, Masterman-Smith M, Geschwind DH, Bronner-Fraser M and Kornblum HI. Cancerous stem cells can arise from pediatric brain tumors. *Proceedings of the National Academy of Sciences of the United States of America.* 2003; 100:15178-15183.
 27. Ignatova TN, Kukekov VG, Laywell ED, Suslov ON, Vrionis FD and Steindler DA. Human cortical glial tumors contain neural stem-like cells expressing astroglial and neuronal markers in vitro. *Glia.* 2002; 39:193-206.
 28. Singh SK, Clarke ID, Terasaki M, Bonn VE, Hawkins C, Squire J and Dirks PB. Identification of a cancer stem cell in human brain tumors. *Cancer Res.* 2003; 63:5821-5828.
 29. Tchoghandjian A, Baeza-Kallee N, Beclin C, Metellus P, Colin C, Ducray F, Adelaide J, Rougon G and Figarella-Branger D. Cortical and subventricular zone glioblastoma-derived stem-like cells display different molecular profiles and differential in vitro and in vivo properties. *Annals of surgical oncology.* 2012; 19:S608-619.
 30. Eckel-Passow JE, Lachance DH, Molinaro AM, Walsh KM, Decker PA, Sicotte H, Pekmezci M, Rice T, Kosel ML, Smirnov IV, Sarkar G, Caron AA, Kollmeyer TM, Praska CE, Chada AR, Halder C, et al. Glioma Groups Based on 1p/19q, IDH, and TERT Promoter Mutations in Tumors. *N Engl J Med.* 2015; 372:2499-2508.
 31. Suzuki H, Aoki K, Chiba K, Sato Y, Shiozawa Y, Shiraishi Y, Shimamura T, Niida A, Motomura K, Ohka F, Yamamoto T, Tanahashi K, Ranjit M, Wakabayashi T, Yoshizato T, Kataoka K, et al. Mutational landscape and clonal architecture in grade II and III gliomas. *Nature genetics.* 2015; 47:458-468.
 32. Reuss DE, Sahm F, Schrimpf D, Wiestler B, Capper D, Koelsche C, Schweizer L, Korshunov A, Jones DT, Hovestadt V, Mittelbronn M, Schittenhelm J, Herold-Mende C, Unterberg A, Platten M, Weller M, et al. ATRX and IDH1-R132H immunohistochemistry with subsequent copy number analysis and IDH sequencing as a basis for an "integrated" diagnostic approach for adult astrocytoma, oligodendroglioma and glioblastoma. *Acta Neuropathol.* 2015; 129:133-146.
 33. Weller M, Weber RG, Willscher E, Riehm V, Hentschel B, Kreuz M, Felsberg J, Beyer U, Loffler-Wirth H, Kaulich K, Steinbach JP, Hartmann C, Gramatzki D, Schramm J, Westphal M, Schackert G, et al. Molecular classification of diffuse cerebral WHO grade II/III gliomas using genome- and transcriptome-wide profiling improves stratification of prognostically distinct patient groups. *Acta Neuropathol.* 2015; 129:679-693.
 34. Kalani MY, Kalani MA, Gwinn R, Keogh B and Tse VC. Embryological development of the human insula and its implications for the spread and resection of insular gliomas. *Neurosurgical focus.* 2009; 27:E2.
 35. Kurth F, Eickhoff SB, Schleicher A, Hoemke L, Zilles K and Amunts K. Cytoarchitecture and probabilistic maps of the human posterior insular cortex. *Cerebral cortex (New York, NY : 1991).* 2010; 20:1448-1461.

36. Zilles K and Amunts K. Receptor mapping: architecture of the human cerebral cortex. *Current opinion in neurology*. 2009; 22:331-339.
37. Kurth F, Zilles K, Fox PT, Laird AR and Eickhoff SB. A link between the systems: functional differentiation and integration within the human insula revealed by meta-analysis. *Brain structure & function*. 2010; 214:519-534.
38. Wang B, Li M, Wu Z, Li X, Li YU, Shi X and Cheng W. Associations between SOX2 and miR-200b expression with the clinicopathological characteristics and prognosis of patients with glioma. *Experimental and therapeutic medicine*. 2015; 10:88-96.
39. Lopez-Bertoni H, Lal B, Li A, Caplan M, Guerrero-Cazares H, Eberhart CG, Quinones-Hinojosa A, Glas M, Scheffler B, Laterra J and Li Y. DNMT-dependent suppression of microRNA regulates the induction of GBM tumor-propagating phenotype by Oct4 and Sox2. *Oncogene*. 2015; 34:3994-4004.
40. Bouvier C, Roll P, Quilichini B, Metellus P, Calisti A, Gilles S, Chinot O, Fina F, Martin PM and Figarella-Branger D. Deletions of chromosomes 1p and 19q are detectable on frozen smears of gliomas by FISH: usefulness for stereotactic biopsies. *Journal of neuro-oncology*. 2004; 68:141-149.